



## SING IMT in pseudophakic eyes: Results of the first experiences

Alfonso Savastano<sup>a,b,1</sup>, Nicola Claudio D'Onofrio<sup>a,b,\*,1</sup>, Giuseppe Francione<sup>a,b</sup>, Paola Sasso<sup>a,b</sup>, Lorenzo Hu<sup>a,b</sup>, Stanislao Rizzo<sup>a,b,c</sup>

<sup>a</sup> Fondazione Policlinico Universitario A. Gemelli IRCCS, Rome, Italy

<sup>b</sup> Università Cattolica Del Sacro Cuore, Rome, Italy

<sup>c</sup> Consiglio Nazionale Della Ricerca (CNR), Istituto di Neuroscienze, Pisa, Italy

## ARTICLE INFO

## Keywords:

Age related macular degeneration  
Low vision  
Visual prosthesis  
Implantable miniature telescope  
SING IMT  
Surgical technique

## ABSTRACT

**Purpose:** To evaluate the feasibility and outcomes of implanting the Smaller-Incision New-Generation Implantable Miniature Telescope (SING IMT) in pseudophakic patients affected by late-stage dry AMD.

**Subjects:** Five pseudophakic patients' eyes with stable dry AMD were suitable for SING IMT implantation. Four eyes were excluded because of previous YAG laser capsulotomy. Patients underwent preoperative assessments, including visual acuity measurements and OCT scans.

**Methods:** Surgical procedures were performed under peribulbar anesthesia, with careful IOL removal and SING IMT implantation. Postoperative follow-up was conducted at regular intervals to monitor visual acuity, device positioning and complications.

**Results:** Postoperative outcomes demonstrated improvements in visual acuity for most patients with an average gain in CDVA (Corrected Distance Visual Acuity) and CNVA (Corrected Near Visual Acuity) of  $16,8 \pm 10,2$  and  $13,8 \pm 7,4$  ETDRS letters, respectively. Limited complications have been observed. In one case, we observed dislocation of the device into the vitreous chamber, which we managed through vitrectomy and scleral fixation of the SING IMT using GoreTex suture.

**Conclusions:** Despite being traditionally contraindicated for pseudophakic patients, SING IMT implantation in selected cases yielded favorable outcomes, indicating potential benefits for this population. Further research with larger sample sizes and longer follow-up periods is warranted to refine patient selection criteria and optimize surgical techniques.

## 1. Introduction

Age-related macular degeneration (AMD) is a disease that causes progressive central vision loss due to damage to the macular region of the retina.<sup>1</sup>

It is a leading cause of irreversible blindness in older people in developed countries. It is estimated that 200 million people worldwide have AMD, and this number is expected to increase to nearly 300 million by 2040.<sup>2</sup>

Different therapeutic options are being explored to treat dry AMD, each with its unique target. These approaches aim to slow the progression of the disease and include drugs with antioxidative properties, complement cascade inhibitors, neuroprotective agents, visual cycle inhibitors, gene therapy, and cell-based therapies.

In order to enhance visual ability in individuals with advanced AMD

various methods have been developed; specialized and individualized rehabilitation programs can train patients to improve their use of residual vision.<sup>3</sup> Electronic or optical magnifiers, colored filters, prism spectacles, and closed-circuit television can aid residual and low-vision individuals in magnifying their central vision in specific contexts. However, external aids have important limitations, including restricted visual fields, cosmetic drawbacks, and the need for continual motion of the head, leading to vestibular effects.

Several companies are developing retinal and intraocular implants as potential treatment options for end-stage AMD to restore some of the lost vision to the patient.<sup>4</sup>

The implantable miniature telescope (IMT) is an ophthalmic device that improves distant and mostly near vision in individuals who have lost bilateral central vision due to wet or dry end-stage AMD.

After implantation, the telescope enlarges objects in the person's

\* Corresponding author. Largo Agostino Gemelli, 8, 00168, Roma RM, Italy.

E-mail address: [nicola.c.donofrio@gmail.com](mailto:nicola.c.donofrio@gmail.com) (N.C. D'Onofrio).

<sup>1</sup> These Authors contributed equally as First Author to this manuscript.

central visual field and focuses them onto healthy areas of the retina that are unaffected by AMD despite a not negligible visual field loss. This allows individuals to recognize objects that would be otherwise difficult to see but, on the other hand, one of the worst drawbacks of the implanted telescope is, indeed, a significant loss of the visual field in the operated eye. In fact, after the surgery, patients will depend entirely on their non-implanted eye to perceive objects on the periphery of their vision. Moreover, postoperatively, all recipients must undergo rehabilitation with a low-vision specialist to learn how to adjust to the device.<sup>3</sup>

## 2. SING-IMT

In the year 2020, the smaller-incision new generation implantable miniature telescope (SING IMT™), the second generation of the implant received approval for utilization within the European Union. SING IMT is an innovative iteration of the IMT device designed to enhance near, mid, and far-range visual acuity in individuals with bilateral, end-stage age-related macular degeneration. In contrast to its predecessor, the SING IMT offers increased magnification (up to  $\times 2.7$  of the central visual field) and simplified implantation procedures. The implantation procedure takes place in an outpatient setting and involves several steps. Initially, the cataract is removed using the standard phacoemulsification technique. Subsequently, the optical component, a glass telescope embedded in a silicon carrier, is injected into the capsular bag. To secure the telescope in place within the ocular capsular bag, silicon haptic wings are utilized. The entire process is made more convenient using a preloaded delivery system (Tsert SI cartridge), which necessitates smaller surgical incisions ranging from 6.5 to 7.5 mm.<sup>5</sup>

SING-IMT is indicated for monocular implantation in patients older than or equal to 55 years of age with stable, severe to profound vision impairment (best corrected distance visual, acuity 20/160 to 20/800) due to end-stage age-related macular degeneration (AMD).

Patients must meet the following criteria:

- have retinal findings of geographic atrophy or disciform scar with foveal involvement,
- evidence of visually significant cataract
- agree to undergo pre-surgery training and assessment with low vision specialists in the use of an external telescope sufficient for patient assessment and for the patient to make an informed decision.
- achieve at least a 5-letter improvement on the ETDRS chart with an external telescope.
- have adequate peripheral vision in the eye not scheduled for surgery.
- agree to participate in postoperative visual training with a low vision specialist<sup>6</sup>

We have investigated the possibility of extending the application of SING IMT to patients with d-AMD that match all the inclusion criteria for SING IMT but the pseudophakic condition. Moreover, these patients were very keen to have the possibility of having SING IMT implanted because of the significant sight improvement they experienced using the External Telescope Simulator (ETS). Even if they have previously undergone cataract surgery, we have proposed an off label surgery (dedicated written consent was obtained) based on the concept of IOL removal and SING IMT implant at the same time.

## 3. Material and methods

We identified 5 patients' eyes that were suitable for SING IMT implantation and IOL removal at the same time. All pseudophakic patients who underwent surgery had a one-piece IOL implanted in the capsular bag. Patients agreed to receive the surgery after having well explained pro and cons and the technical difficulty of the procedure. We have already described our standard technique for eyes affected by cataract and dry AMD.<sup>7</sup> This study was conducted in adherence to the principles outlined in the Declaration of Helsinki and received approval from the

Ethics Committee of Catholic University. Surgery was performed at Policlinico A. Gemelli, Rome, Italy. We explained to the patient risks and benefits of the procedure, then a proper informed consent was obtained. Prior to the surgical procedure, each patient underwent a series of examinations for enrollment. The inclusion and exclusion criteria used were the same as for standard SING IMT, except for the pseudophakic condition. In pseudophakic patients, we excluded those who had undergone YAG laser capsulotomy. Best-corrected visual acuity (BCVA) for distance was assessed using the Early Treatment of Diabetic Retinopathy Study (ETDRS) chart at 4 m. Near vision was also evaluated utilizing the ETDRS chart. Intraocular pressure (IOP) was measured with a Goldmann applanation tonometer. A comprehensive examination of the anterior segment and fundus was conducted through slit-lamp examination, followed by optical coherence tomography (OCT) using Optovue Solix Fullrange OCT. Axial length (AL) and anterior chamber depth (ACD) were assessed through optical biometry using the ZEISS IOLMaster® 500. Corneal endothelial cell density (ECD) was measured using specular microscopy with the CSO Endothelial Microscope Perseus.

A simulator utilizing an external telescope lens (ETS) was employed to replicate the impact of implanting a Galilean telescope intraocular lens in both eyes. The total number of letters read with the ETS, and the corresponding improvement compared to the initial Best-Corrected Visual Acuity (BCVA) were documented. Additionally, the patients' mobility was assessed while alternately covering both eyes. An eye was deemed suitable for the implant only if the gain in reading letters with the ETS was  $\geq 5$  letters. The eye with better visual acuity, demonstrating an ETS improvement of  $\geq 5$  letters compared to the contralateral eye without ETS, was selected for the implant. In cases where both eyes exhibited the same visual acuity, the eye preferred for mobility was chosen for the surgery.

We opted to replace the existing intraocular lens (IOL) after simulation indicated a substantial enhancement in visual acuity. Furthermore, the patient expressed a strong desire for the surgery and was willing to adhere to post-surgery rehabilitation.

We performed surgeries under peribulbar anesthesia (5 ml lidocaine 0.2 %; 0.5 mL ropivacaine).

Two paracenteses were made and dispersive viscoelastic was injected in the anterior chamber. An 8.0 mm sclerocorneal incision was done at the 12-o'clock position, after opening of the conjunctiva and Tenon's capsule beneath the corresponding clock hours. Scleral bleeding was coagulated using bipolar coagulation forceps. The IOL was explanted from its capsular bag using nucleus manipulator or IOL hook or both. In all the cases the IOL resulted very adherent to the capsular bag and mostly the haptics than the optic plate. For this reason, if the haptics resulted too adherent to the capsular bag, the surgeons (SR/AS) decided to cut and leave them stuck in the bag, otherwise to remove them entirely. However, such a tight adherence was never observed at the level of the optic plate that was removed without any complications in all the reported cases.

SING IMT™ implant is pre-loaded into the Tsert delivery system, which includes the cartridge and injector. Right before implanting the device, the injector was prepared following the provided instructions. The preloaded system enables the surgeon to prepare the device for injection in less than 1 min. This is achieved by unlocking the Tsert plunger and pushing it until the surgeon confirms that the device is loaded and properly positioned through the upper window. The final step involves removing the unintended injection blocker from the syringe plunger. Importantly, before injecting the implant, the empty space of the injector tip was filled with a cohesive viscoelastic. SING-IMT was then injected into the anterior chamber and the positioning of the SING IMT cloud have been both in the ocular ciliary sulcus and the capsular bag (preferred choice if possible) according to the capsular bag condition. After checking the lens was in proper position, sclerocorneal incision was secured using 5 single 10-0 monofilament nylon sutures. The cohesive.

viscoelastic was then removed. Paracentesis were sealed with BSS

(balanced salt solution). Intracameral cefuroxime (0.1 mL) was injected, and the conjunctiva was sutured using 2 single absorbable sutures (Vycril 10-0).

4. Results

Only in two cases we were able to implant the lens in the capsular bag. In the other 3 cases, although the capsular bag was intact, it was stiffly collapsed and impossible to expand. Therefore, the SING IMT was implanted in ciliary sulcus (Table 1).

Patients were seen the day after, at 1 week, 15 days, and 1 and 3 months, as per our protocol.

During follow-up, we didn't observe corneal edema or endothelial failure. Although, this represents a small number of cases, the cumulative surgical maneuvers and post-operative inflammation could have caused damage and therefore loss of endothelial cells. No patient experienced an elevation of IOP; we never needed to administer or add hypotensive eye drops during the follow-up (Table 2).

Given the difficulty in visualizing the fundus through the device via ophthalmoscopy, we relied on full-range OCT to assess the macula. None of the observed patients developed macular edema during the scheduled post-operative checks.

In 4 out of 5 cases, the lens was in the correct position, and we did not observe tilting in either the lateral or antero-posterior direction. In one case, a posterior capsular rupture was observed following the implantation of the SING IMT into the capsular bag. However, despite this complication, the SING IMT appeared to be relatively stable, leading us to conclude the surgery. During the three-month follow-up, this patient reported a sudden and severe decrease in visual acuity. Upon examination, we observed a dislocation of the SING IMT into the vitreous chamber. Therefore, we scheduled a 23-gauge vitrectomy. We opted to secure the nasal haptic using an 8.0 GoreTex suture, as the other two haptics in the sulcus appeared stable. Consequently, a small scleral incision was created 1.5 mm from the limbus using a 30-degree blade. Two double-armed 8-0 GoreTex sutures were passed through the scleral incision to access the nasal haptic in the anterior chamber. The curved needles were inserted through the nasal silicon haptic from the outside of the eye to the inside, passing through the sclera, while stabilizing the haptic with ILM forceps. Subsequently, each loose end of the GoreTex was sutured using 25-gauge crocodile vitreous forceps.<sup>8</sup>

The patient then underwent regular follow-up checks and started rehabilitation without any further complications.

Baseline CDVA and NDVA in our cohort was  $11,4 \pm 7,2$  and  $37,6 \pm 16,3$  ETDRS letters, respectively. Three-months after surgery the average CDVA and NDVA increased to  $28,2 \pm 6,3$  and  $51,4 \pm 20,5$  ETDRS letters, respectively.

A rehabilitation training program was developed at Policlinico Gemelli Hospital by a team of ophthalmologists, surgeons, and orthoptists. Starting six weeks post-surgery, this program aims to improve visual abilities, reading, writing, visual motor integration, and mobility. Conducted over a maximum period of six months, the training includes

regular sessions focusing on improving visual function and adapting to changes post-surgery. Specific exercises, particularly for reading, are tailored for macular degeneration and involve techniques to support ocular coordination and vision clarity.

5. Discussion

The Implantable Miniature Telescope, IMT (by Dr Isaac Lipshitz), (IMT VisionCare Ophthalmic Technologies, Saratoga, California) is designed for its placement into the capsular bag after cataract extraction.<sup>9</sup>

Due to the strong motivation and request from the patients, we have decided to offer this possibility of implant to pseudophakic patients as well (usually an exclusion criteria). For safety reasons, we excluded patients with YAG laser capsulotomy from the study. Specifically, we were concerned about the possibility of vitreous prolapse into the anterior chamber after removing the monofocal lens or the entire capsular bag rupture during SING-IMT implantation. While these are our assumptions, it cannot be ruled out that the device could be implanted in individuals who have undergone YAG laser capsulotomy.

In patients we have operated, the significant improvement recorded using the ETS preoperatively (more than 20 ETDRS letters in each patient) associated with their strong motivation to follow the rehabilitation program, allowed us to reach quite a good result compared with the standard technique.<sup>5,10</sup> The surgical procedure, despite proven to be safe, is not entirely without risks. Over time, the haptics of the one piece monofocal IOL previously implanted, become strongly adherent to the posterior capsule. For this reason, during the removal of the IOL, we were only able to preserve the posterior capsule and implant the SING IMT into the capsular bag in two cases.

In two cases we were obliged to cut the monofocal IOL haptic otherwise the risk of a capsular dislocation was too high trying to remove them. Surprisingly, that did not bring any negative consequence to the SING IMT implant and surgical come out.

In cases where we implanted the lens in the sulcus, we did not observe differences in terms of improvement in visual acuity, post-surgical complications, and/or patient satisfaction in 3 months follow-up. However, the data we have are limited by the small sample size of patients and still need to be evaluated with long-term follow-up.

In one of the two patients in whom we had implanted the IOL in the capsular bag, at 1 month the device dropped into the vitreous chamber; presumably, the already fragile capsular bag did not withstand the weight of the device and overtime gave way. In this case, we repositioned the lens to the sclera using 8.0 Gore-Tex sutures (Fig. 1).

In our experience, we did not observe any other cases of device dislocation into the vitreous chamber. However, Eter, N. and Behr, O. similarly described a case of zonular dehiscence following SING IMT implantation, which was resolved by scleral fixation of a haptic using a 10-0 prolene suture.<sup>11</sup>

6. Conclusion

Many of the patients with advanced dry AMD who come to our attention are likely pseudophakic, and for this reason, they may not be eligible for SING IMT. We have therefore decided to try including pseudophakic patients in selected few cases (off label procedure) who have not undergone YAG laser capsulotomy. Despite the surgical procedure being more complex and not without risks, the group of patients who underwent surgery showed no differences in terms of post-operative complications and visual recovery at 3 months. Although our study is limited by the small sample size, pseudophakic patients could represent an additional group of patients able to benefit from this device or this kind of technology.

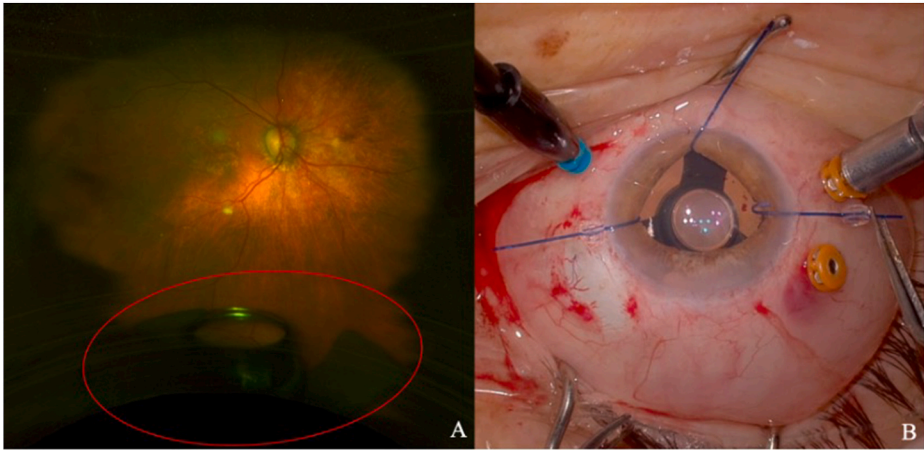
Table 1  
IOL type and SING-IMT final position after surgery.

Patient	IOL type	SING-IMT final position	Post-operative Dislocation/tilting
1	Monofocal one-piece IOL	Capsular bag	Late dislocation in vitreous chamber
2	Monofocal one-piece IOL	Capsular bag	Centered
3	Monofocal one-piece IOL	Ciliary sulcus	Centered
4	Monofocal one-piece IOL	Ciliary sulcus	Centered
5	Monofocal one-piece IOL	Ciliary sulcus	Centered

**Table 2**  
Change in CDVA, CNVA, IOP, ECD and ACD from baseline at 3 months after SING-IMT™ implantation.

Patient	CDVA (ETDRS)	CNVA (ETDRS)	IOP	ECD	ACD	CDVA 3 months (ETDRS)	CNVA 3 months (ETDRS)	IOP 3 months	ECD 3 months	ACD 3 months
1	19 letters	38 letters	10 mmHg	2466	3.231	25 letters	51 letters	10 mmHg	2319	2.901
2	4 letters	52 letters	14 mmHg	2507	3.042	41 letters	56 letters	16 mmHg	2456	2.691
3	1 letter	4 letters	18 mmHg	2017	3.770	21 letters	10 letters	15 mmHg	1880	3.850
4	21 letters	53 letters	12 mmHg	2550	3.503	29 letters	77 letters	14 mmHg	2499	3.215
5	12 letters	41 letters	18 mmHg	2365	3.398	25 letters	63 letters	18 mmHg	2238	3.101

CDVA: Correct distance visual acuity; CNVA: Correct near visual acuity; IOP: Intraocular pressure; ECD: Endothelial cell density; ACD: anterior chamber depth.



**Fig. 1.** (A) SING-IMT™ dropped in the vitreous chamber (red circle) and subsequent repositioning after vitrectomy and scleral fixation with 8.0 Gore-Tex sutures (B).

**Patient consent**

Consent to publish this case report has been obtained from the patients in writing.

**Funding**

No funding or grant support.

**CRedit authorship contribution statement**

**Alfonso Savastano:** Writing – review & editing, Writing – original draft, Supervision, Investigation. **Nicola Claudio D’Onofrio:** Writing – review & editing, Writing – original draft, Supervision, Investigation, Data curation. **Giuseppe Francione:** Investigation, Data curation. **Paola Sasso:** Data curation. **Lorenzo Hu:** Data curation. **Stanislao Rizzo:** Supervision.

**Declaration of competing interest**

The authors declare that they have no known competing financial interests or personal relationships that could have appeared to influence the work reported in this paper.

**Acknowledgments**

None.

**Appendix A. Supplementary data**

Supplementary data to this article can be found online at <https://doi.org/10.1016/j.ajoc.2024.102119>.

[org/10.1016/j.ajoc.2024.102119](https://doi.org/10.1016/j.ajoc.2024.102119).

**References**

1. Coleman HR, Chan C-C, Ferris FL, Chew EY. Age-related macular degeneration. *Lancet*. 2008;372(9652):1835–1845. [https://doi.org/10.1016/S0140-6736\(08\)61759-6](https://doi.org/10.1016/S0140-6736(08)61759-6).
2. Vyawahare H, Shinde P. Age-related macular degeneration: epidemiology, pathophysiology, diagnosis, and treatment. *Cureus*. 2022;14(9), e29583. <https://doi.org/10.7759/cureus.29583>.
3. Hudson HL, Lane SS, Heier JS, et al, IMT-002 Study Group. Implantable miniature telescope for the treatment of visual acuity loss resulting from end-stage age-related macular degeneration: 1-year results. *Ophthalmology*. 2006;113(11):1987–2001. <https://doi.org/10.1016/j.ophtha.2006.07.010>.
4. Maghami MH, Sodagar AM, Lashay A, Riazi-Esfahani H, Riazi-Esfahani M. Visual prostheses: the enabling technology to give sight to the blind. *J Ophthalmic Vis Res*. 2014;9(4):494–505. <https://doi.org/10.4103/2008-322X.150830>.
5. Savastano A, Ferrara S, Sasso P, et al. Smaller-incision new-generation implantable miniature telescope: three-months follow-up study. *Eur J Ophthalmol*. 2023, 11206721231212545. <https://doi.org/10.1177/11206721231212545>.
6. Premarket Approval (PMA). <https://www.accessdata.fda.gov/scripts/cdrh/cfdocs/cfpma/pma.cfm?id=P050034> (accessed 2024-March-21).
7. Savastano A, Caporossi T, Sasso P, De Vico U, Rizzo S. A new intraocular telescopic device for age-related macular degeneration. *Ophthalmol Retina*. 2022;6(10): 971–972. <https://doi.org/10.1016/j.oret.2022.05.017>.
8. Savastano A, Sammarco LA, Francione G, Sasso P, Rizzo S. Scleral fixation of the smaller-incision new-generation implantable miniature telescope (SING IMT™) using GoreTex suture. *Retin Cases Brief Rep*. 2024. <https://doi.org/10.1097/ICB.0000000000001572>.
9. Lipshitz I, Loewenstein A, Reingewirtz M, Lazar M. An intraocular telescopic lens for macular degeneration. *Ophthalmic Surg Laser*. 1997;28(6):513–517.
10. Toro MD, Vidal-Aroca F, Montemagni M, Xompero C, Fioretto G, Costagliola C. Three-month safety and efficacy outcomes for the smaller-incision new-generation implantable miniature telescope (SING IMT™). *J Clin Med*. 2023;12(2):518. <https://doi.org/10.3390/jcm12020518>.
11. *Scleral fixation of the Smaller-Incision New Generation Implantable Miniature Telescope (SING IMT™) | Graefe’s Archive for Clinical and Experimental Ophthalmology*. <https://link.springer.com/article/10.1007/s00417-024-06444-7> (accessed 2024-May-19).